

## Retrospective Study

# Full-Endoscopic Decompression with the Application of an Endoscopic-Matched Ultrasonic Osteotome for Removal of Ossification of the Thoracic Ligamentum Flavum

Jun-Song Yang, MD<sup>1</sup>, Han-Lin Gong, MD<sup>2</sup>, Hao Chen, MD<sup>1</sup>, Jian-Min Wei, MD<sup>3</sup>, Chien-Min Chen, MD<sup>4</sup>, Zi-Jun Gao, MD<sup>5</sup>, Zi-Long Zhang, MD<sup>1</sup>, Ding-Jun Hao, MD<sup>1</sup>, Yuan-Ting Zhao, MD<sup>1</sup>, and Lei Chu, MD<sup>6</sup>

From: <sup>1</sup>Department of Spine Surgery, Honghui Hospital, Xi'an Jiaotong University, Shaanxi, China; <sup>2</sup>Department of Integrated Traditional Chinese and Western Medicine, West China Hospital, Sichuan University, Chengdu, PR China; <sup>3</sup>Department of Spine Surgery, Baoji City Hospital of Traditional Chinese Medicine, Shaanxi, China; <sup>4</sup>Department of Neurosurgery, Changhua Christian Hospital, Changhua City, China; <sup>5</sup>School of Medicine, Kaohsiung Medical University, Kaohsiung, China; and <sup>6</sup>College of Nursing and Health Sciences, Dayeh University, Changhua City, China; <sup>7</sup>Department of Anesthesiology, Honghui Hospital, Xi'an Jiaotong University, Shaanxi, China; <sup>8</sup>Department of Orthopaedics, The Second Affiliated Hospital, Chongqing Medical University, Chongqing, China

Address Correspondence:  
Yuan-Ting Zhao, MD  
Department of Spine Surgery,  
Honghui Hospital, Xi'an Jiaotong  
University, Xi'an, Shaanxi, China  
E-mail: doczhaoyuanting@163.com

Disclaimer: Authors J-S.Y., H-L.G., H.C., J-M.W., L.C., and Z-J.G. contributed equally to this study.

Conflict of interest: Each author certifies that he or she, or a member of his or her immediate family, has no commercial association (i.e., consultancies, stock ownership, equity interest, patent/licensing arrangements, etc.) that might pose a conflict of interest in connection with the submitted manuscript.

Manuscript received: 06-24-2020  
Revised manuscript received: 09-29-2020  
Accepted for publication: 10-01-2020

Free full manuscript: [www.painphysicianjournal.com](http://www.painphysicianjournal.com)

**Background:** Resection of the ossification of the thoracic ligamentum flavum (OTLF) with a high-speed burr may cause a high rate of perioperative complications, such as dural laceration and/or iatrogenic spinal cord injury.

**Objectives:** The aim of this study was to investigate the safety and feasibility of the endoscopic-matched ultrasonic osteotome in full-endoscopic spinal surgery for direct removal of OTLF.

**Study Design:** Retrospective study.

**Setting:** All data were from Honghui Hospital in Xi'an.

**Methods:** This study conducted between December 2017 and December 2018, included 27 consecutive patients who met the study criteria, had single-level OTLF, and underwent full-endoscopic decompression under local anesthesia. The postoperative follow-up was scheduled at 1, 3, 6, and 12 months postoperatively. Outcomes evaluations included the Visual Analog Scale (VAS) score for lower extremity pain and the modified Japanese Orthopaedic Association (mJOA) score and improvement rate for the assessment of thoracic myelopathy. Removal of OTLF was measured by comparing the pre- and postoperative computed tomography (CT) and magnetic resonance imaging (MRI) scans.

**Results:** The operation was completed in all patients without conversion to open surgery. The operation time ranged from 65 to 125 minutes (average, 83.7 ± 12.3 minutes). All patients were followed up for 12 to 18 months, with an average follow-up of 14.3 ± 1.3 months. Satisfactory neurologic decompression was confirmed by postoperative CT and MRI, and no revision surgery was required. The VAS and mJOA scores showed statistically higher improvement at the 1-month follow-up and the last follow-up compared with the preoperative assessment ( $P < 0.05$ ). According to the improvement rate at the final follow-up, 20 cases were classified as good, 6 cases were fair, and 1 case remained unchanged.

**Limitations:** A single-center, noncontrol study.

**Conclusions:** The endoscopic-matched ultrasonic osteotome can be considered quite safe and feasible for direct removal of OTLF during full-endoscopic spinal surgery in strictly selected patients, as this allows for effective direct decompression of OTLF while minimizing trauma and instability. In addition, because of the design characteristics of the ultrasonic osteotome, surgical complications, especially dural tears and spinal cord injury, can also be effectively controlled.

**Key words:** Percutaneous endoscopic spinal surgery, ultrasonic osteotome, ossification of thoracic ligamentum flavum, microsurgery, thoracic myelopathy, minimally invasive procedures

**Pain Physician 2021; 24:275-281**

Ossification of the thoracic ligamentum flavum (OTLF) is characterized by the replacement of the ligamentum flavum by ectopic new bone formation. As one of the causes of thoracic myelopathy, OTLF mainly causes compression of the spinal cord on the posterolateral side, resulting in slowly progressive paralysis or acute numbness and/or weakness of the lower limbs with or without sphincter dysfunction following trauma (1).

The current treatment for OTLF is surgical extirpation of the ossified ligamentum flavum by laminectomy owing to its progressive nature and poor response to conservative therapy. Posterior decompression procedures include traditional open laminectomy with or without posterior fusion and minimally invasive procedures, such as microendoscopic decompression and percutaneous endoscopic decompression (2-9). The calcified ligamentum flavum may adhere to the dura mater and has inherent space constraints; hence resection of the ossification of the ligamentum flavum with a high-speed burr may cause a high rate of perioperative complications, such as dural laceration and/or iatrogenic spinal cord injury leading to transient neurologic deterioration or permanent paraplegia.

An ultrasonic osteotome, an instrument based on piezoelectric high-frequency mechanical vibration, is capable of selective bone cutting and the optimal preservation of the adjacent soft tissue (10,11). Based on successful experiences using the instrument in oral and maxillofacial surgery (12,13), the application of ultrasonic osteotomes in spinal surgery is increasing (14). Yu et al (15) first introduced the ultrasonic osteotome for the percutaneous transforaminal endoscopic decompression of the calcified intravertebral disc and

observed satisfactory clinical outcomes. The high tissue selectivity of ultrasonic osteotomes allows for safe and effective endoscopic decompression in OTLF. The aim of this study was to investigate the safety and feasibility of the endoscopic-matched ultrasonic osteotome in full-endoscopic spinal surgery for direct removal of OTLF.

## METHODS

This retrospective study conducted between December 2017 and December 2018, included 27 consecutive patients who met the study criteria, had single-level OTLF, and underwent full-endoscopic decompression under local anesthesia. Patients were 16 men and 11 women with an average age of  $54.7 \pm 8.5$  years (range, 41–67 years). The duration of preoperative symptoms ranged from 3 to 23 months. The lesion distribution was as follows: 3 involved the upper thoracic spine (T1–T4), 6 involved the middle thoracic spine (T5–T8), and 18 involved the lower thoracic spine (T9–T12).

The inclusion criteria were single-segment OTLF with definite thoracic myelopathy, characterized by weakness in the lower extremities, gait disturbances, dorsal pain, and/or sphincter dysfunction; compromise of thoracic spinal cord by OTLF confirmed by computed tomography (CT) with or without magnetic resonance imaging (MRI) (Fig. 1A–C); neurologic deficit corresponding to the targeted lesion as located on preoperative MRI/CT; and lateral, extended, or enlarged type of OTLF detected on the preoperative CT scan according to the Sato (16) classification for OTLF.

The exclusion criteria were as follows: multisegmental OTLF or concomitant with cervical or lumbar lesions; fusion or tuberous type of OTLF (16); accom-

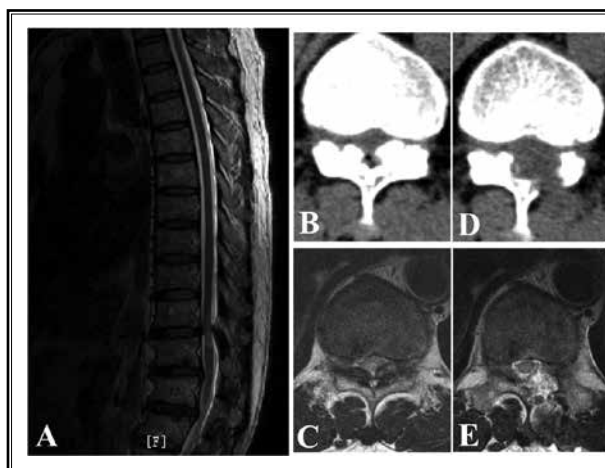


Fig. 1. Preoperative T2-weighted MRI of the thoracic spine showed spinal cord was compressed by low-signal masses at the level of T10/11 in the sagittal section (A). The axial plane of MRI showed the spinal cord compression was caused by the low-signal masses attached to the bilateral lamina (C), which were classified as the extended type at the CT scan of the thoracic spine (B). Satisfactory decompression was completed after the left laminotomy, which was confirmed by the axial planes of CT scan (D) and MRI (E).

panying ventral compression, including thoracic disc herniation and/or ossification of the posterior longitudinal ligament, and severe cardiopulmonary disease that could not tolerate surgery; and lost to follow-up less than 12 months.

The medical ethics committees of our hospitals approved the study in accordance with the relevant guidelines and regulations. Informed consent was obtained from all patients.

### Surgical Equipment

The main surgical instruments included the endoscopic system and bipolar radiofrequency (Spinendos GmbH, München, Germany), and the endoscopic-matched ultrasonic osteotome device consisted of a host machine, a handpiece, and different types of disposable tips (XD880A, SMTP, Beijing, China) (Fig. 2).

### Surgical Technique

All surgeries were performed by an attending spinal surgeon who had performed nearly 1,000 endoscopic spinal procedures. The patient was placed in the prone position on a radiolucent table under local anesthesia. Thus it was convenient for patients to receive timely feedback during the whole operation. The local anesthetic agent used consisted of a 20-mL mixture of lidocaine, bupivacaine, and saline solution at a ratio of 1:1:1. Dexmedetomidine (0.5 µg/kg initial bolus, followed by 0.1–0.5 µg/kg/hour) was injected intravenously to provide the desired level of sedation. Based on the OTLF location, a 2-cm skin incision was

made on the more severe side of the spinal stenosis approximately 1 to 2 cm from the midline. An 18-gauge spinal needle was inserted under fluoroscopic guidance toward the lamina at the level of the OTLF lesion (Fig. 3A, B). Then, a guidewire was placed, and the needle removed. Sequential dilation was performed along the guidewire. A working cannula was established, and its position was confirmed by fluoroscopy at the surgical target-OTLF. The endoscope was inserted through the working cannula (Fig. 3C). In patients with unilateral compression, ipsilateral laminotomy was performed with the assistance of an ultrasonic osteotome via endoscopy (Figs. 3D and 4). In patients with bilateral OTLF, the contralateral sublaminar portion was decompressed by sublaminar shaving through the base of the spinal process, similar to the technique of “over-the-top” decompression (17). We used endoscopic forceps to remove the unossified ligamentum flavum and soft

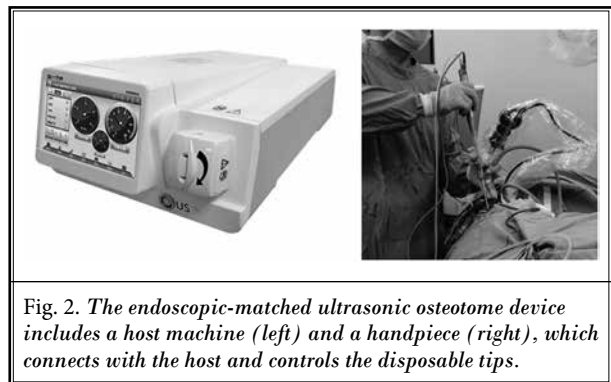


Fig. 2. The endoscopic-matched ultrasonic osteotome device includes a host machine (left) and a handpiece (right), which connects with the host and controls the disposable tips.

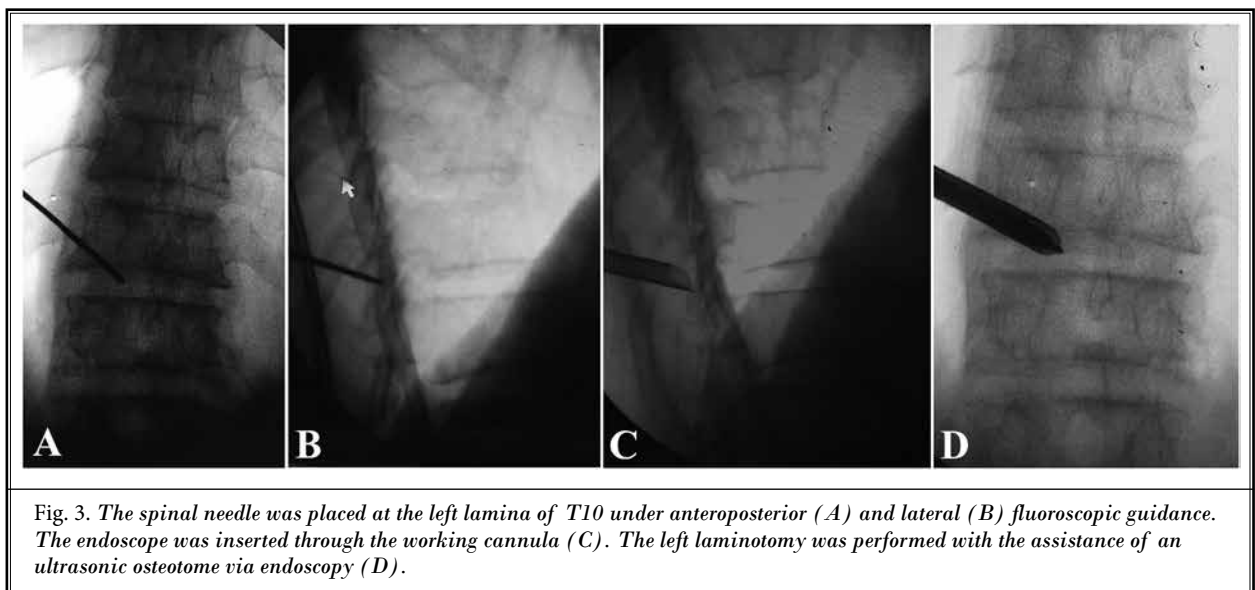


Fig. 3. The spinal needle was placed at the left lamina of T10 under anteroposterior (A) and lateral (B) fluoroscopic guidance. The endoscope was inserted through the working cannula (C). The left laminotomy was performed with the assistance of an ultrasonic osteotome via endoscopy (D).

tissue in the midline. The ossified ligamentum flavum was removed safely and efficaciously layer by layer by the cavitation effect of the ultrasonic osteotome (Fig. 5A). For the patients without dural adhesions, the inner

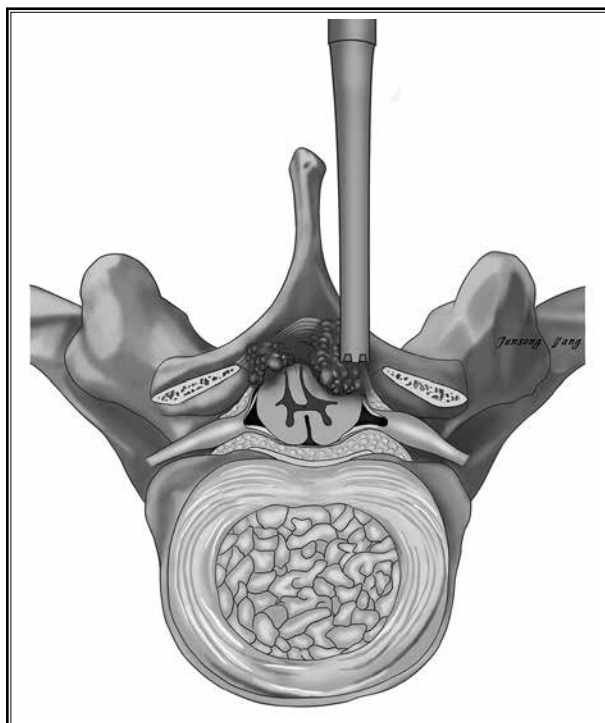


Fig. 4. The schematic diagram shows the left laminotomy was performed with the assistance of an ultrasonic osteotome via endoscopy.

layer of ossified ligamentum flavum can be removed by the endoscopic punch (Fig. 5B). A clear space between the dural sac and the lamina and dural pulsation were considered the signs of thorough neural decompression (Fig. 5C). A drain catheter was placed and retained for 24 hours to prevent epidural hematoma. Patients were kept in bed for 6 hours after surgery and asked to avoid strenuous exercise for 1 month.

#### Follow-Up and Observation Indicators

The postoperative follow-up was scheduled at 1, 3, 6, and 12 months postoperatively. Outcomes evaluations included the Visual Analog Scale (VAS) score for lower extremity pain and the modified Japanese Orthopaedic Association (mJOA) score for the assessment of thoracic myelopathy (18). The mJOA improvement rate is calculated as follows: (postoperative mJOA score – preoperative mJOA score) / (11 – preoperative mJOA score) × 100%. An improvement rate of 50% or greater was good, 25% to 50% was fair, less than 25% was unchanged, and 0% was deteriorated (19). Removal of OTLF was measured by comparing the pre- and postoperative CT and MRI scans.

#### Statistical Analysis

All statistical analyses were performed using the GraphPad Prism 8.0.2 software (GraphPad, San Diego, CA). Quantitative variables are presented as mean ± standard deviation. The paired t-test was used to compare the pre- and postoperative VAS and mJOA scores. A *P* value < 0.05 was considered statistically significant.

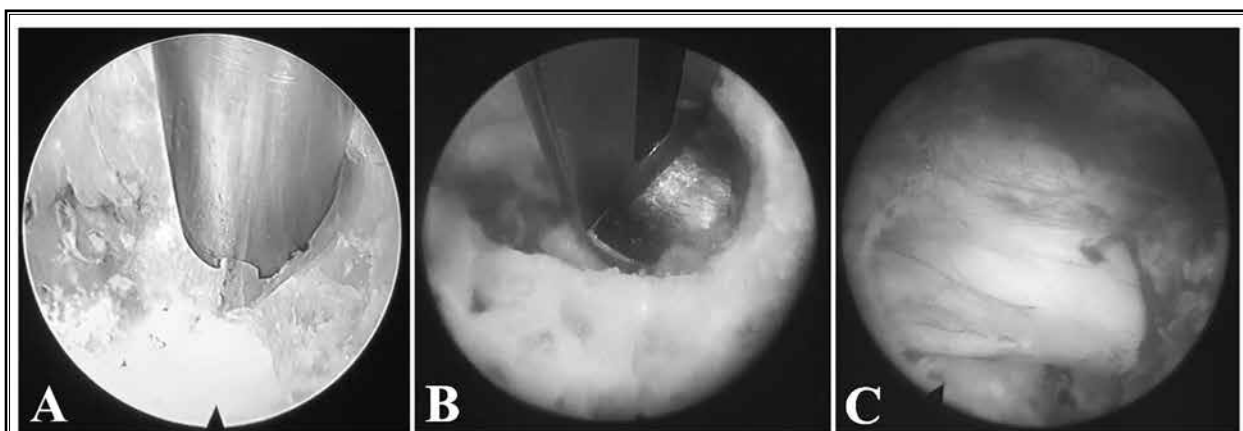


Fig. 5. The ossified ligamentum flavum was removed safely and efficaciously layer by layer by the cavitation effect of the ultrasonic osteotome (A). For the patients without dural adhesions, the inner layer of the ossified ligamentum flavum can be removed by the endoscopic punch (B). A clear space between the dural sac and the lamina was observed after the thorough neural decompression (C).

## RESULTS

The operation was completed in all patients without conversion to open surgery. The operation time ranged from 65 to 125 minutes (average,  $83.7 \pm 12.3$  minutes). No catastrophic complications occurred during surgery in any patient, such as major vascular injury, spinal cord injury, pleural effusion formation, or dural laceration. All patients were followed up for 12 to 18 months, with an average follow-up of  $14.3 \pm 1.3$  months. No patient complained of the aggravation of neurologic symptoms, surgical site infection, delayed healing, or epidural hematoma postoperatively. Satisfactory neurologic decompression was confirmed by postoperative CT and MRI, and no revision surgery was required. The VAS score, mJOA score, and mJOA improvement rate are summarized in Table 1. The VAS and mJOA scores showed statistically higher improvement at the 1-month follow-up and the last follow-up compared with the preoperative assessment ( $P < 0.05$ ). According to the improvement rate at the final follow-up, 20 cases were classified as good, 6 cases were fair, and 1 case remained unchanged.

## DISCUSSION

The universal and classic treatment for OTLF is bilateral laminectomy and excision of the affected lesion. In this procedure, the inferior articular processes and the inferior laminae of the superiorly located vertebra are removed, following which OTLF is ground into a paper-thin plate and finally removed. Although the surgery provides thorough neural decompression, the tremendous surgical trauma involving the paraspinal muscles, spinous processes, and the attached ligaments can impair rapid postoperative recovery. Additionally, surgical complications, such as increased postoperative laminectomy-related kyphosis and/or intersegmental instability can occur (20).

Percutaneous endoscopic spine surgery, one of the most minimally invasive spinal surgical techniques, can achieve targeted decompression with minimized surgical trauma based on improvements in equipment and optical technology. The iatrogenic damage to the paraspinal muscles, facet joints, laminae, and posterior ligamentous complexes is minimized, and hence the risk of postoperative instability is controlled. Microendoscopic decompression for thoracic canal stenosis is also less invasive with an easier learning curve over conventional laminectomy (4,5). However, full-endoscopic decompression performed under local anesthesia has the advantage of obtaining the patient's real-time

Table 1. Comparison of the VAS score, the mJOA score, and mJOA improvement rate of patients before surgery, 1 month after surgery, and at the last follow-up ( $x \pm s$ ).

	Preoperatively	1 Month Postoperatively	Final Follow-Up
VAS score	$5.9 \pm 0.9$	$2.2 \pm 0.7^*$	$1.3 \pm 0.4^{*#}$
mJOA score	$6.2 \pm 0.8$	$7.3 \pm 0.8^*$	$8.9 \pm 1.0^{*#}$
mJOA improvement rate	–	–	58.8%

\*Compared with preoperatively  $P < 0.001$ .

#Compared with 1 month postoperatively  $P < 0.001$ .

feedback; moreover, continuous saline irrigation can generate hydraulic pressure to reduce intraoperative bleeding and decrease the risk of infection. Several authors have described their preliminary experiences with percutaneous endoscopic decompression for the treatment of OTLF under local anesthesia (7,8,21). However, dural tears and the transient worsening of preoperative paralysis remain the main complications. In our study, all patients achieved satisfactory improvement of neurologic function without developing either complication, and this may be attributed to strict patient selection and the application of the endoscopic-matched ultrasonic osteotome. Sato (16) classified OTLF into 5 types, including lateral, extended, enlarged, fused, and tuberos types. Based on the morphologic characteristics, individualized treatment was recommended (16). Decompression by laminotomy or laminoplasty is necessary for lateral or extended type without dural adhesions. Considering the degrees of OTLF and the stenosis of the spinal canal, the fuse or tuberos type of OTLF may be higher than the other 3 types and can be appropriately treated by en bloc laminectomy via open surgery. However, dural ossification is a problem that cannot be ignored, the reported rate of which ranged from 11% to 40% in all types of OTLF (22). In cases of dural ossification, traditional surgical decompression is demanding and complications such as dural laceration, cerebrospinal fluid (CSF) leakage, pseudomeningocele, and iatrogenic spinal cord injury could be more frequent.

In the current treatment of thoracic spinal stenosis, high-speed burr has demonstrated advantages such as efficiency in bone cutting and has become the most common surgical instrument. However, the disadvantages of high-speed burr are also obvious. During continuous high-speed rotation for bone cutting, the scraping injury of the surrounding tissues and handle



slippage are quite common, which increase the risk of iatrogenic injury to the dural sac and even the spinal cord (23). An ultrasonic osteotome converts electrical energy into mechanical energy through a piezoelectric transducer, allowing the blade to vibrate at an appropriate ultrasonic frequency, and bone cutting is achieved by mechanical fragmentation and cavitation effects of the ultrasonic waves (10,11). Moreover, it has the advantages of high tissue selectivity, easy handling, good anti-rolling, and low working temperatures over traditional surgical tools (15). Because of differences in tissue density and elastic properties, an ultrasonic osteotome has only a selective cutting role in hard structure bony tissue rather than in soft tissue, especially the dural sac. In the presence of dural ossification, the use of an ultrasonic osteotome reduces the risk of dural tear while achieving complete decompression of the dural surface. The handle vibration is lower than the rotational torque with high-speed burr during surgery, thus decreasing the learning curvature. An ultrasonic osteotome adopts longitudinal fretting of the cutter instead of the axial rotation of the burr; hence the design concept is different. The cutter cannot be easily wrapped by the surrounding soft tissues, which helps limit the surgical injury to the adjacent muscular and neural structures. Its cavitation effect can reduce local bleeding to maintain a clear field, which is necessary to sustain the irrigative pressure at an appropriate level during the operation, thereby reducing the incidence of high perfusion-related complications, such as spinal cord injury, intracranial hypertension, dizziness, and epileptic seizures. Additionally, the blunted design and the related temperature control features (working temperature  $<40^{\circ}$  for the ultrasonic osteotome) of the cutter are important for reducing mechanical cutting injury and thermal damage in the surgical area, especially when removing OTLF from the surface of the dural sac. Several studies have proven that an ultrasonic osteotome can indeed induce lower risk of CSF, shorter operation time, and smaller intraoperative blood loss than a high-speed burr can (24-27). Yu et al (15) first attempted to utilize an ultrasonic osteotome to remove a calcified disc protrusion and observed ideal clinical outcomes with no complications of dural tear or infection. We believe that the advantages of a magnified and clear field and adjustable visual angle in percutaneous spinal surgery combined with high tissue selectivity of the ultrasonic osteotome can further achieve efficient and safe decompression of

OTLF. In our study, both the radiographic and clinical outcome were satisfactory; and average operation time was only  $83.7 \pm 12.3$  minutes. There were no adverse events, such as major vascular injury, spinal cord injury, pleural effusion formation, or dural laceration in any patients intraoperatively.

The main limitation of our study is the retrospective nonrandomized controlled study design. Although an ultrasonic osteotome may be safer and more efficient than conventional techniques for decompressing the bony structure, because of the learning curve of endoscopic surgery we suggest that beginners with certain experience in endoscopic decompression surgery should start using endoscopic-matched ultrasonic osteotomes to perform the removal of OTLF via endoscopy.

## CONCLUSIONS

An endoscopic-matched ultrasonic osteotome can be considered quite safe and feasible for direct removal of OTLF during full-endoscopic spinal surgery in strictly selected patients, as this allows for effective direct decompression of OTLF while minimizing trauma and instability. In addition, because of the design characteristics of the ultrasonic osteotome, surgical complications, especially dural tears and spinal cord injury, can also be effectively controlled. However, further prospective, randomized controlled studies are required to determine whether endoscopic-matched ultrasonic osteotome indeed improves the safety and efficacy of endoscopic decompression for OTLF compared with high-speed burr.

## Authors' Contributions

Ding-Jun Hao and Yuan-Ting Zhao conceived the study design. Han-Lin Gong, Hao Chen, Jian-Min Wei, Lei Chu, Chien-Min Chen, Zi-Long Zhang, and Zi-Jun Gao supervised the data collection and literature review. Jun-Song Yang drafted the manuscript. Yuan-Ting Zhao is responsible for this article.

## Funding Disclaimer

Supported by the Chinese National Natural Science Foundation (No. 81830077 for D-J.H.), Project of China Post-Doctoral Research Fund (project no. 2016M602943XB), Basic Scientific Research Operating Expenses (Natural Science) Scientific Research Project of Central University (project no. XZY012019124), and Shaanxi Province Post-Doctoral Research Fund Enterprise Project (project no. 2017BSHQYXMZZ19).

## REFERENCES

1. Yamada T, Torigoe I, Sakai K, et al. Contiguous multilevel thoracic ossification of ligamentum flavum in a young adult spine. *Case Rep Orthop* 2019; 2019:1640485.
2. Jia LS, Chen XS, Zhou SY, et al. En bloc resection of lamina and ossified ligamentum flavum in the treatment of thoracic ossification of the ligamentum flavum. *Neurosurgery* 2010; 66:1181-1186.
3. Hirabayashi H, Ebara S, Takahashi J, et al. Surgery for thoracic myelopathy caused by ossification of the ligamentum flavum. *Surg Neurol* 2008; 69:114-116; discussion 116.
4. Baba S, Oshima Y, Iwahori T, et al. Microendoscopic posterior decompression for the treatment of thoracic myelopathy caused by ossification of the ligamentum flavum: A technical report. *Eur Spine J* 2016; 25:1912-1919.
5. Ikuta K, Tarukado K, Senba H, et al. Decompression procedure using a microendoscopic technique for thoracic myelopathy caused by ossification of the ligamentum flavum. *Minim Invasive Neurosurg* 2011; 54:271-273.
6. Jia ZQ, He XJ, Zhao LT, et al. Transforaminal endoscopic decompression for thoracic spinal stenosis under local anesthesia. *Eur Spine J* 2018; 27:465-471.
7. An B, Li XC, Zhou CP, et al. Percutaneous full endoscopic posterior decompression of thoracic myelopathy caused by ossification of the ligamentum flavum. *Eur Spine J* 2019; 28:492-501.
8. Miao X, He D, Wu T, et al. Percutaneous endoscopic spine minimally invasive technique for decompression therapy of thoracic myelopathy caused by ossification of the ligamentum flavum. *World Neurosurg* 2018; 114:8-12.
9. Xiaobing Z, Xingchen L, Honggang Z, et al. "U" route transforaminal percutaneous endoscopic thoracic discectomy as a new treatment for thoracic spinal stenosis. *Int Orthop* 2019; 43:825-832.
10. Schaeren S, Jaquiéry C, Heberer M, et al. Assessment of nerve damage using a novel ultrasonic device for bone cutting. *J Oral Maxillofac Surg* 2008; 66:593-596.
11. Salami A, Dellepiane M, Salzano FA, et al. Piezosurgery in the excision of middle-ear tumors: Effects on mineralized and non-mineralized tissues. *Med Sci Monit* 2007; 13:Pi25-29.
12. Vercellotti T, Dellepiane M, Mora R, et al. Piezoelectric bone surgery in otosclerosis. *Acta Otolaryngol* 2007; 127:932-937.
13. Amghar-Maach S, Sánchez-Torres A, Camps-Font O, et al. Piezoelectric surgery versus conventional drilling for implant site preparation: A meta-analysis. *J Prosthodont Res* 2018; 62:391-396.
14. Kim K, Isu T, Matsumoto R, et al. Surgical pitfalls of an ultrasonic bone curette (SONOPET) in spinal surgery. *Neurosurgery* 2006; 59:ONS390-ONS393; discussion ONS393.
15. Yu L, Wen JK, Wang S, et al. Removal of calcified lumbar disc herniation with endoscopic-matched ultrasonic osteotome: Our preliminary experience. *Br J Neurosurg* 2020; 34:80-85.
16. Sato T. Surgical treatment for ossification of ligamentum flavum in the thoracic spine and its complications. *Spine Spinal Cord* 1998; 11:505-510.
17. Ruetten S, Hahn P, Oezdemir S, et al. Full-endoscopic uniportal decompression in disc herniations and stenosis of the thoracic spine using the interlaminar, extraforaminal, or transthoracic retropleural approach. *J Neurosurg Spine* 2018; 29:157-168.
18. Hirabayashi K, Miyakawa J, Satomi K, et al. Operative results and postoperative progression of ossification among patients with ossification of cervical posterior longitudinal ligament. *Spine (Phila Pa 1976)* 1981; 6:354-364.
19. Li M, Meng H, Du J, et al. Management of thoracic myelopathy caused by ossification of the posterior longitudinal ligament combined with ossification of the ligamentum flavum: A retrospective study. *Spine J* 2012; 12:1093-1102.
20. Aizawa T, Sato T, Ozawa H, et al. Sagittal alignment changes after thoracic laminectomy in adults. *J Neurosurg Spine* 2008; 8:510-516.
21. Cheng XK, Chen B. Percutaneous endoscopic thoracic decompression for thoracic spinal stenosis under local anesthesia. *World Neurosurg* 2020; 139:488-494.
22. Ahn DK, Lee S, Moon SH, et al. Ossification of the ligamentum flavum. *Asian Spine J* 2014; 8:89-96.
23. Burke SM, Hwang SW, Safain MG, et al. Iatrogenic spinal cord injury during removal of the inferior articular process in the presence of ossification of the ligamentum flavum. *Case Rep Surg* 2016; 2016:2318759.
24. Hazer DB, Yaşar B, Rosberg HE, et al. Technical aspects on the use of ultrasonic bone shaver in spine surgery: Experience in 307 patients. *Biomed Res Int* 2016; 2016:8428530.
25. Al-Mahfoudh R, Qattan E, Ellenbogen JR, et al. Applications of the ultrasonic bone cutter in spinal surgery--Our preliminary experience. *Br J Neurosurg* 2014; 28:56-60.
26. Hu X, Ohnmeiss DD, Lieberman IH. Use of an ultrasonic osteotome device in spine surgery: Experience from the first 128 patients. *Eur Spine J* 2013; 22:2845-2849.
27. Sanborn MR, Balzer J, Gerszten PC, et al. Safety and efficacy of a novel ultrasonic osteotome device in an ovine model. *J Clin Neurosci* 2011; 18:1528-1533.

